

ECVSMR Sample questions 2019

Part 1 MCQ:

What describes the Vertical Impuls ?

It represents the area under the force curve

It defines the force related to the body mass

It defines the force related to the body weight

It is a basic kinematic parameter

What is the most important method of heat loss for exercising dogs?

Evaporation

Radiation

Conduction

Convection

Hydrotherapy equipment allows the regulation of water temperature. What is the cardiovascular response to exercise in cold water?

Heart rate decreases and stroke volume increases

heart rate decreases and stroke volume decreases

heart rate increases and stroke volume increases

heart rate increases and stroke volume decreases

Guttural pouch mycosis most commonly involves which cranial nerves?

IX and X

X and XI

VIII and X

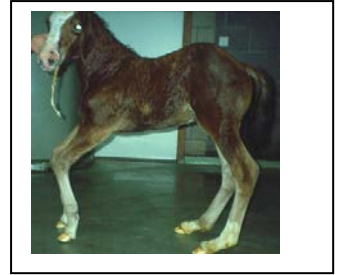X and XII

Part 2 cases:

A 1 week-old foal was born with a forelimb flexural limb deformity as illustrated in the picture; it can only stand up for short periods of time.

List 4 examinations which are indicated in this young foal.

- *Inspection/palpation/ultrasonographic examination of common digital extensor tendon (to check for rupture)*
- *Measure the degree of deformation*
- *Radiographic examination of the carpus for incomplete ossification*
- *Ultrasonographic examination of umbilicus (check for infection)*
- *Blood sample for IgG analysis (failure of passive transfer of immunity)*




What would your initial treatment plan look like?

- *Anti-inflammatory and anti-ulcer medication (1 point)*
- *Oxytetracycline (3g IV)*
- *Manual stretching/cast or splint if unable to stand and nurse*

Another foal (4 weeks old) is presented with the following abnormality.

List 4 possible differential diagnoses.

- *Ruptured common digital extensor tendon*
- *Synovial sepsis elbow or shoulder joint*
- *Olecranon fracture*
- *Radial paralysis*



Upon closer inspection, a swelling on the distal cranial lateral aspect of the antebrachium extending to the carpus is observed.

What is your diagnosis and treatment plan?

- *Ruptured common digital extensor tendon*
- *Rest & splint bandage*

